耳朵人体全息图

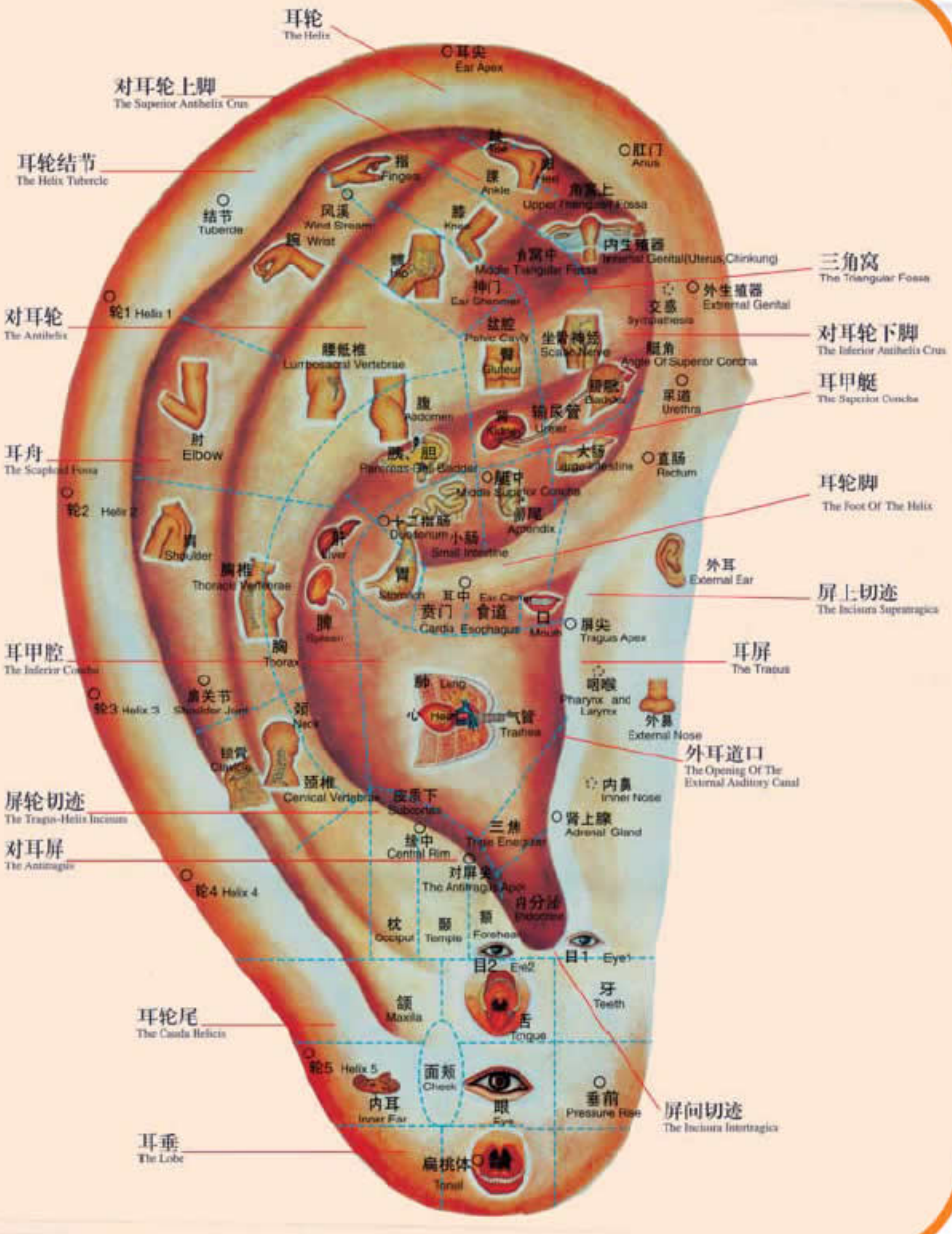

耳轮
The Helix
耳尖
Ear Apex
对耳轮上脚
The Superior Anthelix Crus
耳轮结节
The Helix Tubercle
结节
Tuberde
指
Fingers
风溪
Wind Stream
腕 Wrist
踝
Ankle
跟
Heel
肛门
Anus
膝
Knee
髋
Hip
内生殖器
Internal Genital(Uterus,Ctinkung)
Middle Triangular Fossa
神门
Ear Shenmen
三角窝
The Triangular Fossa
外生殖器
External Genital
交感
Sympathesis
轮1 Helix 1
对耳轮
The Antihelix
腰骶椎
Lumbosacral Vertebrae
盆腔
Pelvic Cavity
坐骨神经
Sciatic Nerve
臀
Gluteur
艇角
Angle Of Superior Concha
对耳轮下脚
The Inferior Antihelis Crus
耳甲艇
The Superior Concha
尿道
Urethra
膀胱
Bladder
腹
Abdomen
输尿管
Ureter
肾
Kidney
肘
Elbow
耳舟
The Scaphoid Fossa
胰、胆
Pancreas-Gall Bladder
大肠
Large Intestine
直肠
Rectum
艇中
Middle Superior Concha
耳轮脚
The Foot Of The Helix
轮2 Helix 2
十二指肠
Duodenum
小肠
Small Intestine
阑尾
Appendix
肩
Shoulder
肝
Liver
胸椎
Thoracic Vertebrae
胃
Stomach
耳中
Ear Center
外耳
External Ear
屏上切迹
The Incisura Supratragica
贲门
Cardia
食道
Esophagus
口
Mouth
屏尖
Tragus Apex
脾
Spleen
胸
Thorax
耳甲腔
The Inferior Concha
耳屏
The Tragus
肺 Lung
咽喉
Pharynx and Larynx
肩关节
Shoulder Joint
轮3 Helix 3
颈
Neck
心 Heart
气管
Trachea
外鼻
External Nose
外耳道口
The Opening Of The External Auditory Canal
锁骨
Clavicle
内鼻
Inner Nose
颈椎
Cervical Vertebrae
皮质下
Subcortex
屏轮切迹
The Tragus-Helix Incisura
肾上腺
Adrenal Gland
缘中
Central Rim
三焦
Triple Energizer
对耳屏
The Antitragus
对屏尖
The Antitragus Apex
轮4 Helix 4
内分泌
Endocrine
枕
Occiput
颞
Temple
额
Forehead
目1 Eye1
目2 Eye2
牙
Teeth
颌
Maxilla
舌
Tongue
耳轮尾
The Cauda Helicis
轮5 Helix 5
面颊
Cheek
内耳
Inner Ear
眼
Eye
垂前
Pressure Rise
屏间切迹
The Incisura Intertragica
耳垂
The Lobe
扁桃体
Tonsil